

Combined Laser Blood Illumination by Red (635 nm) and UV (365-405 nm) Light in the Treatment of Small Domestic Animals with Allergic Dermatitis

Tatiana L. Yatskevich¹, Olga N. Semenova² and Sergey V. Moskvina^{3,*}

¹ Veterinarian of "InnoVet" veterinary center, Frunze prosp., 130, Tomsk 634021, Tomsk Region, Russia, tel.: +7 (923) 410-4672, e-mail: tiger-hl@ya.ru

² Assistant professor of veterinary department of Tomsk Agricultural Institute of FSBEI of Higher Education Novosibirsk State Agrarian University, Solyanaya pl., 11, Tomsk 634003, Tomsk region, Russia, Candidate of Biological Sciences, tel.: +7 (903) 953-9924, e-mail: olja.tomsk@mail.ru

³ Leading researcher of the State Research Center of Laser Medicine FMBA of Russia, Studencheskaya ul., 40, Moscow 121165, Russia, Candidate of Engineering Sciences, Doctor of Biological Sciences, tel.: +7 (916) 987-9095, e-mail: 7652612@mail.ru

* Author to whom correspondence should be addressed.

Abstract

Background: The prevalence of atopic dermatitis in domestic animals is one of the problems of modern veterinary. Treating with standard techniques using chemotherapeutic agents not always leads to a positive result of therapy; moreover, many drugs produce adverse side effects. **Methods:** Low level laser therapy, in particular, intravenous laser blood illumination (ILBI) has a pronounced and long-lasting impact on the immune system of animals. The combined technique including ILBI-635 (635 nm, 2 mW, 5 min) and LUVBI® (365 nm, 2 mW, 3 min) every other day provides a positive change in clinical status of cats with allergic dermatitis after the 3rd-4th treatment session. **Results:** The increased level of erythrocytes and hemoglobin was identified in the course of treatment, and it indirectly indicates increased blood transport activity, which improves trophic provision and microcirculation. A double reduction of leukocytes and a significant decrease of neutrophil cells indicate the immunomodulatory effect of LILI (low-intensity laser illumination). The increase in the percentage of lymphocytes and the decrease of eosinophils and monocytes against the background of basophil concentrations deviations within physiological concentration result in the reduction of inflammatory mediators expression that induce itching. The reduction of total IgE concentration 32 times against control on the 7th day of treatment correlates with the decrease in the quantitative content of peripheral blood eosinophils, indicating the decrease in severity of an allergic process. **Conclusion:** LLLT is recommended against the background of standard drug therapy to achieve quick clinical outcome together with a long-lasting prolonged effect.

Keywords: veterinary; allergic dermatitis; low level laser therapy

Introduction

Feline skin diseases are among the most frequent nowadays. According to the recent data, in practice, the vet faces skin pathologies in 30% of all the cases, about 10% of them are skin problems purely, the rest are the symptoms of the underlying disease. The prevalence of allergic dermatitis, flea dermatitis mostly, is one of the most urgent problems in domestic animals. [1].

Pathogenetic (standard) treatment of most allergic dermatitis consists in prescribing corticosteroids during 7-10 days with the following reducing the dose to the minimum effective. The main effects are: anti-inflammatory, immunosuppressive, and antipruritic. But these drugs while being used systemically produce a number of side effects (polyuria, polydipsia, polyphagia, hyperglycemia, glycosuria), moreover, treatment outcome is not stable and not prolonged [2].

That is why, the search for new effective and safe, having a long-term remission ways of treatment of small domestic animals with allergic dermatitis is still an urgent task.

Low level laser therapy (LLLT) is one of the most common methods of physiotherapeutic treatment, the safety of which as an evolutionary stage of the heliotherapy development was proved long ago [3], and its therapeutic effect is due to the exposure (illumination) by low intensity laser illumination (LILI) with the power of 1 to 100 mW by different techniques [4]. Low level laser therapy is successfully used in almost all the fields of modern medicine: urology, neurology, dentistry, pediatrics, otorhinolaryngology, gynecology, etc. [5; 6; 7; 8; 9; 10; 11].

One of the most known laser therapy techniques is intravenous laser blood illumination (ILBI) [12, 13]. By now ILBI-635 by red LILI with the wavelength of 635 nm, which influences tissue trophic provision more effectively, and laser ultraviolet blood illumination - LUVBI® (wavelength is 635 nm) have become the most widespread, and the best way is to alternate the procedures by different techniques every other day [14; 4]. There are reports about a successful implementation of ILBI in both options, but only in treatment of large livestock animals [15, 16].

Unfortunately, laser therapy is not so widely used in veterinary, it is used in treatment of livestock more often [17; 15; 18; 19; 20], and in treatment of pets more rarely (cats and dogs, basically) [21; 22]. Nevertheless, there is interest in this effective and safe method in Russia as well as in other countries [23, 24].

The limited use of LLLT, in our opinion, is due to the imperfection of the technology of the procedure implementation in animals, due to the peculiarities of laser exposure techniques for veterinary and to the misunderstanding of some aspects of the mechanisms of the biological effect (BE) of LILI. We are speaking about secondary processes; the primary mechanism of the therapeutic (biological) effect of low energy laser light has been studied in details [24], which contributes much to the successful laser therapy technology promotion.

Among numerous responses of a living organism to laser illumination such as vasodilatation, increased microcirculation, activation of cell metabolism, improvement of tissue trophic provision, hypoxia reduction, etc. the immunomodulatory effect occupies a special place due to the extraordinary multiplicity of factors regulating the immune system, which are in complex relationships and are controlled by the nervous system [4]. Furthermore, the immune system of mammals, even primates, is in many ways fundamentally different from the human [26], that is why, the already known regularities of human responses to laser exposure cannot be automatically transformed into animals. Although, there are common features and principles.

In the available sources of information we could not find even a single scientific publication devoted to the theme of the article directly (laser therapy, not only ILBI, in treatment of allergic dermatitis in animals), but there are related publications in general, for instance, it is shown that LILI has the immunomodulatory effect [27], positive results of treatment of dogs with pyogenic granuloma have been obtained [28]. The efficiency of LLLT with atopic dermatitis is questioned in one study [29], but it is noteworthy that the authors have chosen very doubtful parameters of the laser therapy technique, which are of primary importance for a positive result [4]. This once again proves the necessity of the competent rationale of the techniques together with their correct realization and clinical LLLT efficacy testing.

There exists an experimental study in which the ability of LILI (conjoined technique, laser phoresis of chitosan locally) to remove the allergen has been demonstrated on Wistar rats, which leads to the decrease in the allergic reaction [30]. But the influence on the immune system has not been studied, and ILBI technique has not been implemented.

There are quite a large number of scientific publications and reports about a successful use of LLLT in medical practice, in treatment of patients with allergic dermatitis in particular [31; 8], that was the basis for the research.

The purpose of the research: to study the low level laser therapy effectiveness in treatment of cats with allergic dermatitis on the dynamics of the main clinical signs, morphological and immunological blood parameters.

Materials and methods

The study has been carried out on the basis of the veterinary clinic of Tomsk Agricultural College (Russia). 20 cats of different breed, sex and age groups with the signs of allergic dermatitis caused by flea bites have been chosen as the object of the study. The diagnosis was determined taking into consideration the anamnesis, the results of general examination, and clinical signs.

Pathophysiology of the allergy to flea bites is not studied thoroughly, however, this type of dermatosis in cats is considered to occur mainly due to immunoglobulins of E class (IgE) mediated by I type reaction with “degranulation” of mast cells and eosinophil increase (eosinophilia). Irritating and allergenic effects are caused by the substances present in flea saliva [32]. Proteins-allergens brought into the dermis by means of contact with macrophages stimulate the production of specific IgE antibodies to them, which are fixed on a number of tissues including mast cells, basophils, eosinophils. Re-entering of flea saliva stimulates the release of the contents of intracellular granules containing inflammatory mediators (histamine, prostaglandins, leukotrienes). These mediators stimulate itching development and inflammatory reactions on the skin [33].

“LASMIK” laser therapy device (produced by Research Center “Matrix”, Russia) was used to implement intravenous laser blood illumination, KL-ILBI-635 laser emitting head (power at the light guide end is 2 mW, and wavelength is 635 nm) was used for ILBI-635; KL-ILBI-365 (power is 2 mW, wavelength is 365 nm) was used for LUVBI®. The exposure for ILBI-635 was 15 minutes, for LUVBI® it was 3 minutes. The therapy course involved 10 daily procedures with the alternation of the techniques every other day (combined technique), ILBI-635 was implemented on odd days (from the first), LUVBI® was implemented on even days [14]. Propofol Lipuro-1% anaesthetic was given before the procedures till sedation.

The dynamics of clinical changes was evaluated by the following signs: fur and skin condition, itching decrease or increase, the speed of skin lesion recovery.

The researchers took blood samples for hematological and immunological testing before treatment, 24 hours after the first procedure (ILBI-635), a day after the second procedure (LUVBI®), on the 7th day of treatment, and then in a week after the end of the course of therapy.

To implement immunological testing whole blood was collected in microcentrifuge test-tubes V=2,0 ml with lithium heparin to obtain plasma (“Sarstedt”, Germany), centrifuged at the relative centrifugal force of 2000 g during 10 min.

Serum immunoglobulin IgE concentration was defined by the immunochemiluminescence method on ACS 180 automatic analyzer (Germany).

A complete blood count was performed by Pentra_60 hematological analyzer (France).

Statistical processing of the results of the study was performed on personal computer with the use of Microsoft Office Excel digital software. The reliability and the degree of differences of the studied parameters were defined with the help of Student’s t-test.

Results and discussion

While studying the clinical signs in cats of the experimental group with the signs of allergic flea dermatitis, itching of different intensity, excitation, and excessive grooming were found.

Pathological skin changes were prevalent and included: miliary dermatitis, lichenification foci, excoriations, crusts, flakes, bilateral symmetric self-induced alopecia, erythematous-papular elements, eosinophilic granuloma complex preferentially localized on the head and the muzzle of the animal, on the distal extremities, and on the back and withers. The skin of three animals outside the lesions was pigmented unevenly, with increased dryness.

Changes in the clinical condition occurred already after the 3rd-4th procedure of the combined therapy of ILBI-635 + LUVBI®. The reduction in the signs of allergic dermatitis was found – itchiness became periodic, the areas of the affected skin decreased, excoriation areas were being covered with the thin dense crust of dried exudation, the severity of the inflammatory reaction decreased, anxiety and excessive grooming disappeared. The signs of the inflammation

disappeared completely on the 10th day of the therapy, coat restoring practically in all the animals began within 7-8 days after the end of the procedures (Fig 2).

The number of erythrocytes and hemoglobin before and after the therapy was at the level of physiological norm. The decrease in the level of erythrocytes and hemoglobin on the 7th day of treatment, presumably, can be due to the improvement of metabolic processes and the occurrence of adaptive mechanisms in the animal body. The increase in the number of erythrocytes observed a day after LUVBI® indicates the increase in the reparative processes, the activation of formed elements of blood, and indirectly indicates the improving of the resistance of erythrocyte membranes [12] (Table 1).

Table 1

Morphological composition of blood of cats with the signs of allergic flea dermatitis before and after ILBI

Parameter, units	Norm	Before treatment (control)	24 hours after the first procedure (LBI-635)	24 hours after the second procedure (LUVBI®)	The 7 th day of the complex therapy	The 7 th day after the end of the therapy
Erythrocytes, $\times 10^{12}/L$	5,3-10	7,164±0,58	7,722±0,40	8,516±0,43	7,282±0,74	8,03±0,82
Hemoglobin, g/L	80-150	113,622±0,76	115,784±0,96	118,538±1,55*	115,48±0,71	157,16±7,14*
Leukocytes, $\times 10^9/L$	5,5-18	8,74±1,02	8,84±1,07	6,794±0,46	8,554±0,57	4,52±0,83*

Note: *- statistically significant differences in relation to control ($P \leq 0,05$);

Laser therapy also contributed to the hemoglobin level increase 24 hours after the ultraviolet illumination exposure and on the 7th day after the end of the therapy in relation to control (Table 1). According to the literature data available the joint increase in the erythrocyte and hemoglobin concentration indicates the increase in blood transport activity due to the oxygen increase mediated by the impact of LILI, which, in turn, improves trophic provision and microcirculation in all organs and tissues [34; 35].

On the 7th day after the end of treatment the level of leukocytes decreased up to 2 times (Table 1). A significant decrease in their number was recorded, which is most likely due to the normalizing effect of the illumination on leukocytes [36]. The obtained data indicate the anti-inflammatory effect of the combined ILBI technique.

The increase in the number of leukocytes was observed on the 7th day of the therapy. This parameter correlates with the increase in the number of monocytes (Table 2), and with the skin inflammation decrease, which indicates the advent of the proliferative stage of inflammation.

While studying the leukogram the similar tendency was found among the cells of neutrophilic series (Table 2). The stabilization of leukocyte count at the level of physiological norm and the decrease in neutrophil granulocytes, as some authors think, are due to the immunomodulatory effect of the red spectrum light as well as ultraviolet light [37].

The combined technique application results in the change in the percentage of lymphocytes (Table 2). In this case lymphocytosis is relative because of the simultaneous decrease in neutrophils. However, there is an opinion that the increase in lymphocytes is due to one of the therapeutic effects of LILI, that is, the elimination of the imbalance of the ratio of the subpopulation of T-helpers/Tsuppressors, which contributes to the fast regression of the inflammatory process in tissues [38].

Table 2

Leukogram of cats with the signs of allergic flea dermatitis before and after ILBI

Parameter, %	Norm	Before treatment (control)	24 hours after the first procedure (ILBI-635)	24 hours after the second procedure (LUVBI®)	The 7 th day of the complex therapy	The 7 th day after the end of the therapy
Lymphocytes	20-55	40,76±5,78	44,2±4,89	50,42±4,60	45,62±4,59	62,94±5,17*
Neutrophils	35-78	47,42±5,55	43,8±4,10	36,14±4,06	42,52±4,37	34,34±4,94
Monocytes	1-4	5,92±0,86	5,6±0,70	6,78±0,28	7,7±0,26	2,14±0,44
Eosinophils	0-4	6,2±0,89	6,14±0,42	6,54±0,37	3,7±0,24	1,22±0,70
Basophils	0-1 (rarely)	0,1±0,05	0,1±0,04	0,1±0,04	0,46±0,09*	0,66±0,10*

Note: *- statistically significant differences in relation to control ($P \leq 0,05$);

Hypersensitivity to flea bites in cats is accompanied by relative monocytosis (5,92±0,86%) and average eosinophilia (6,2±0,89%), the appearance of a small amount of basophils (0,1±0,05%), which conditions the allergic process and the occurrence of the inflammatory reaction (Table 2). Under LILI exposure the decrease in eosinophils was observed on the 7th day of treatment, the maximum reduction was reported on the 7th day after the end of the course of therapy (up to 1,22±0,70 %). A similar reduction in monocytes was registered on the 7th day after the end of treatment (from 5,92±0,86 to 2,14±0,44 %).

As far as basophils are concerned, the changes in their number occurred within the physiological constant. Hence, the application of ILBI-635 + LUVBI® combined technique in treatment of cats with allergic dermatitis contributes to the decrease in cytotoxic activity of eosinophils, to the decreased level of monocytes, which results in the reduction in mediators expression inducing inflammation and itching.

To assess the degree of the influence of the method under study on the humoral immunity of cats with hypersensitivity to flea bites, the blood serum test was carried out to define immunoglobulin (IgE) concentration (Table 3).

Table 3

Concentration of serum IgE in cats with the signs of allergic flea dermatitis before and after ILBI

Parameter, ME/ml	Norm	Before treatment (control)	24 hours after the first procedure (ILBI-635)	24 hours after the second procedure (LUVBI®)	The 7 th day of the complex therapy	The 7 th day after the end of the therapy
IgE	0-20	128,812±14,17	117,858±9,17	107,572±5,64	14,572±2,41	3,22±1,80

Note: *- statistically significant differences in relation to control ($P \leq 0,05$);

The parameter of total IgE in blood serum decreased from 128,812±14,17 IU/ml to 14,572±2,41 IU/ml on the 7th day of treatment, and up to 3,22±1,80 IU/ml by the end of the study (Table 3). In Fig.1 it is shown that the change in the concentration of total IgE in blood serum correlates with the decrease in the quantitative content of eosinophils in peripheral blood (from 6,2±0,89 % to 1,22±0,70 %), which indicates the decrease in severity of the allergic reaction.

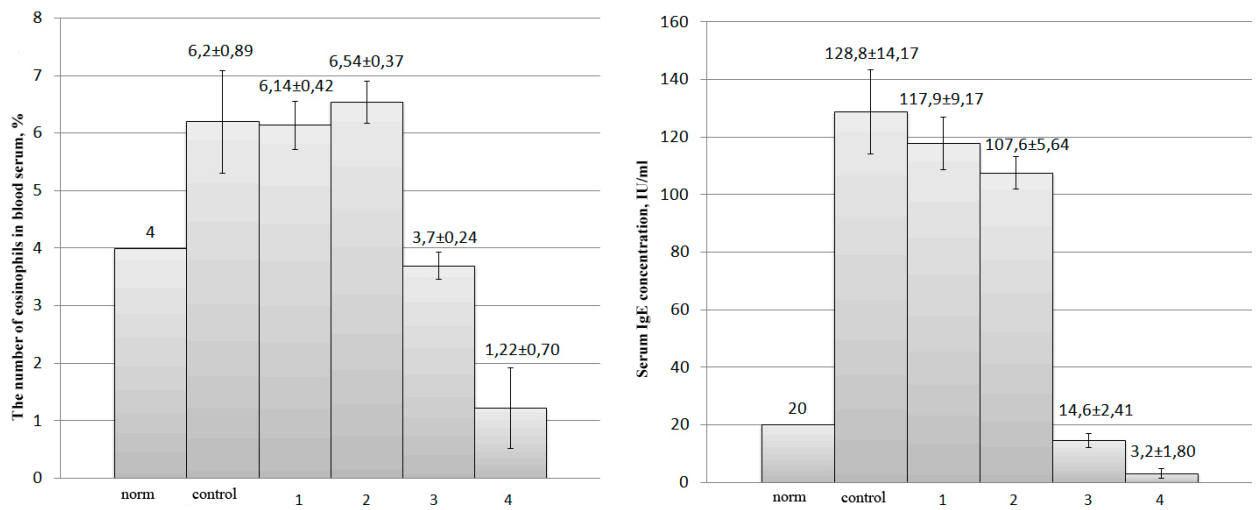


Fig. 1. The correlation between IgE concentration and the number of eosinophils in cats with the signs of allergic flea dermatitis: norm, control – before treatment, 1 – 24 hours after the first ILBI procedure, 2 – 24 hours after the first LUVBI procedure, 3 – the 7th day of the complex therapy, 4 – the 7th day after the end of the therapy

Clinical results are shown in Fig. 2.

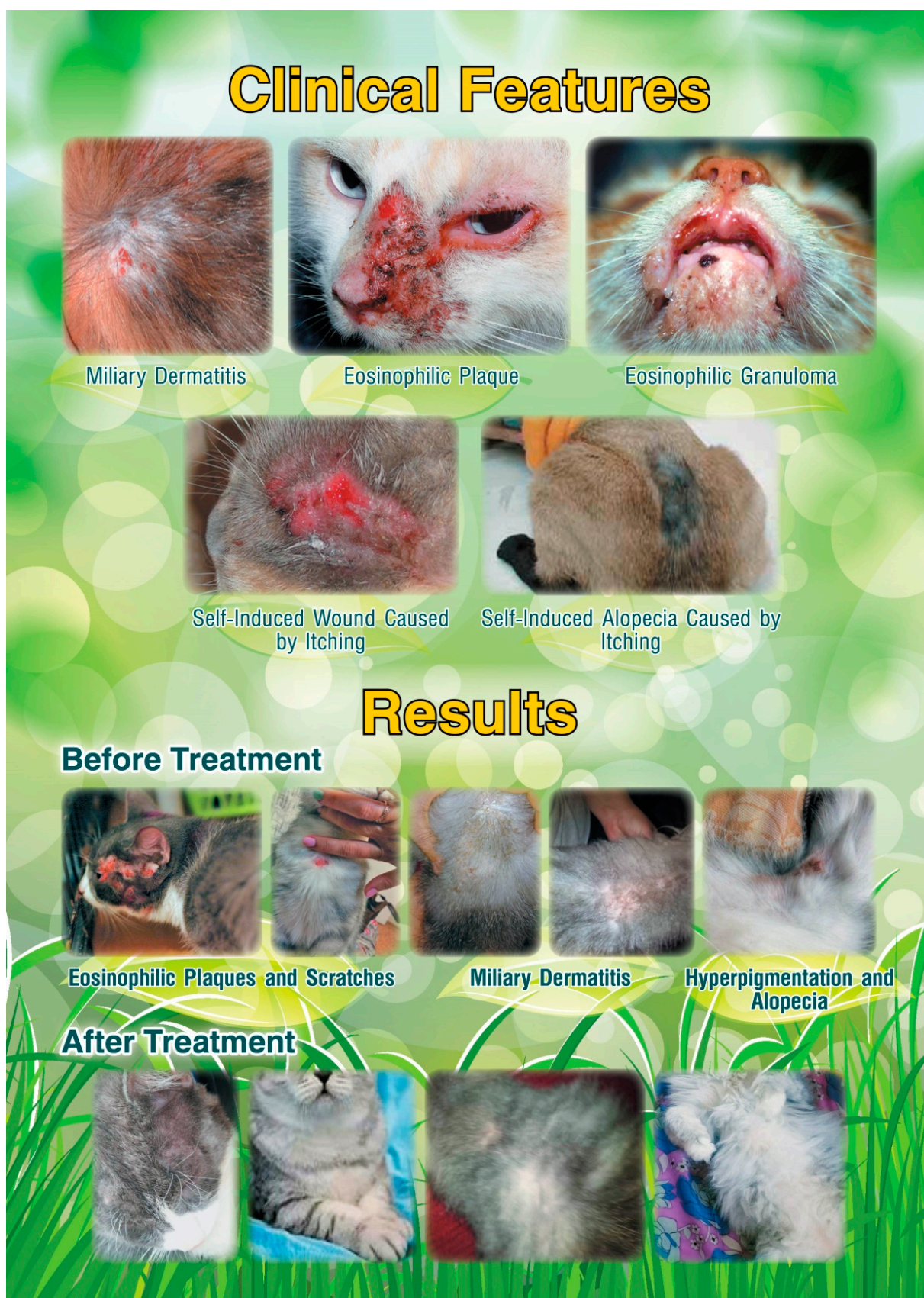

Fig. 2. Clinical features and results

The data obtained make it possible to state that the influence and nature of the therapeutic action of complex LLLT in cats with hypersensitivity to flea bites are reflected in the positive dynamics of the clinical picture of the disease, morphological composition of blood, regenerative function of the skin, serum IgE concentration decrease.

The effectiveness of ILBI-635 + LUVBI® combined technique as pathogenetic therapy with allergic flea dermatitis is proved by itching reduction, inflammatory reaction relief, stimulation of regenerative processes of the skin mediated by the improvement of the microcirculation of tissues.

The LLLT efficiency is also proved by the results of clinical -laboratory- and immunological blood tests, namely: by increase in reparative processes, activation of formed elements of blood, normalization of leukocyte count, elimination of imbalance of lymphoid cells, decrease in IgE secretion.

We draw attention to the fact that this therapeutic method does not imply the use of chemotherapeutic agents.

Conclusion

Positive changes in the clinical condition of cats with allergic dermatitis were found as a result of the combined laser therapy with the use of ILBI after the 3rd-4th session already. Itchiness became periodic, anxiety and excessive grooming disappeared, the decreased areas of the affected skin and inflammatory reaction of the skin were found. The signs of the inflammation disappeared completely on the 10th day of treatment, and the restoration of the coat was reported in 7 days after the therapy.

The synchronous increase in the level of erythrocytes and hemoglobin was registered, and it indirectly indicates the increased blood transport activity, which improves trophic provision and microcirculation in all organs and tissues.

A double reduction in leukocytes and a significant decrease in neutrophil cells occur, which indicates the immunomodulatory effect of LILI.

The increase in the percentage of lymphocytes and the decrease in eosinophils and monocytes against the background of basophil concentration deviation within physiological concentration result in the reduction of inflammatory mediators expression that induce itching.

The 32 time reduction in total IgE concentration against control on the 7th day of treatment correlates with the decrease in the quantitative content of peripheral blood eosinophils, indicating the decrease in severity of the allergic process.

On the basis of the obtained data it is possible to draw a conclusion that the combined laser blood illumination technique (ILBI-635 + LUVBI® every other day) in cats with allergic dermatitis with hypersensitivity to flea bites forms a new approach to treatment aimed at the relief of pathogenetic links with the reduced dosage of chemotherapeutic agents, which increases the safety and the effectiveness of treatment in general. The study can serve as the basis for the implementation of this technique in veterinary practice and be a prerequisite for the further study of the possibilities of the technique.

Author Contributions

The authors contributed equally to this work.

Conflicts of Interest

The authors declare no conflict of interest.

References

1. O'Dair, H.A.; Markwell, P.J.; Maskell I.E. An open prospective investigation into aetiology in a group of cats with suspected allergic skin disease. *Veterinary Dermatology*. **1996**, 7(4), 193-202.
2. Shkvarya, N.N.; Semenov, A.V.; Shagun K.N. Negative effects of glucocorticoids in treatment of allergic dermatitis in cats. *Science and Technology Bulletin of Scientific research center for biosafety and environmental control of agro-industrial complex*. **2015**, 3(1), 46-49.
3. Moskvina, S.V. Laser therapy as a modern stage of heliotherapy (the historical aspect). *Laser medicine*. **1997**, 1(1), 44-49.

4. Moskvina, S.V. *Basics of laser therapy*. Series "Effective laser therapy". Vol. 2. Triada: Moscow–Tver, 2016.
5. Ivanchenko, L.P.; Kozdoba, A.S.; Moskvina S.V. *Laser therapy in urology*. Triada: Moscow–Tver, 2009.
6. Kochetkov, A.V.; Moskvina, S.V.; Karneev A.N. *Laser therapy in neurology*. Triada: Moscow–Tver, 2012.
7. Moskvina, S.V.; Amirkhanyan A.N. *Combined and conjoined laser therapy techniques in dentistry*. Triada: Moscow–Tver, 2011.
8. Moskvina, S.V.; Nasedkin, A.N.; Osin, A.Ya.; Khan M.A. *Laser therapy in pediatrics*. EKSMO: Moscow, 2010.
9. Mufaged, M.L.; Ivanchenko, L.P.; Moskvina S.V. et al. *Laser therapy in urology*. Triada: Tver, 2007.
10. Nasedkin, A.N.; Moskvina S.V. *Laser therapy in otorhinolaryngology*. Triada: Moscow–Tver, 2011.
11. Fedorova, T.A.; Moskvina, S.V.; Apolikhina I.A. *Laser therapy in obstetrics and gynecology*. Triada: Moscow–Tver, 2009.
12. Geynits, A.V.; Moskvina, S.V.; Achilov A.A. *Intravenous laser blood irradiation*. Triada: Moscow–Tver, 2012.
13. Kapustina, G.M.; Moskvina, S.V.; Titov M.N. Intravenous laser blood irradiation (ILBI). *Medical Marketing & Media*. 1996, 24, 20-21.
14. Geynits, A.V.; Moskvina S.V. *New technologies of intravenous laser blood illumination: "ILBI+UVBI" and "ILBI-405"*. Triada: Moscow, 2010.
15. Golubtsov, A.V.; Vasilisin V.V. Application of low intensity laser radiation in order to raise hypothrophic calves autarcesis. *Voronezh State Agrarian University Bulletin*. **2010**, (25), 51-59.
16. Skryl, V.Yu. The efficiency of application of ultraviolet intravascular laser blood illumination in treatment of horses with musculo-skeletal injuries. *Bulletin of Poltavsky State Agrarian Academy*. **2013**, 4, 104-106.
17. Burdov, G.N. Low intensity laser for treatment and prevention of gynecological diseases of pigs. *Veterinariya*. **2002**, 1, 35-37.
18. Kabisov, V.E. Viability, productivity and morphological characteristics of broiler chickens under "Matrix" laser illumination. Abstract of the thesis. Candidate of agricultural sciences. Vladikavkaz, 2011.
19. Maltseva, B.M. The experience of laser application in treatment of animals [cattle]. *Veterinariya. Referativnyy zhurnal*. **2002**, 3, 798.
20. Mamukaev, M.N.; Tokhtiev, T.A.; Kabisov V.E. et al. Indices of chicken broilers' productivity when irradiating with laser Matrix. *Gorsky State Agrarian University News*. **2011**, 48(1), 135-138.
21. Kurochkin, A.A.; Degtyarev O.A. *Quantum therapy of domestic animals*. Moscow, 2004.
22. Persaeva, N.S. Aetiopathogenetic therapy of dogs' inflammatory processes. *Gorsky State Agrarian University News*. **2015**, 52(1), 101-107.
23. Ben-Yakir, S. Veterinary low reactive-level laser therapy (VLRLT). *The Journal of Traditional Veterinary Medicine*. **2012**, 20(1),33-36.
24. Calin, M.A.; Coman T. The laser in veterinary medicine. *Turk. J. Vet. Anim. Sci.* 2011, 35(5), 351-357.
25. Moskvina, S.V. About mechanism of therapeutic influence of low-frequency laser radiation. *Bulletin of new medical technologies*. **2008**, 15(1), 167–172.
26. Male, D.; Brostoff, J.; Roth, D.; Roitt I. *Immunology*. Logosphere: Moscow, 2007.
27. de Oliveira, R.G.; Aarestrup, F.M.; Miranda C. et al. Low-level laser therapy reduces delayed hypersensitivity reaction to ovalbumin in Balb/C mice. *Photomedicine and Laser Surgery*. **2010**, 28(6), 773-777.

28. Perego, R.; Proverbio, D.; Zuccaro, A.; Spada E. Low-level laser therapy: Case-control study in dogs with sterile pyogranulomatous pododermatitis. *Veterinary World*. **2016**, 9(8): 882-887. doi: 10.14202/vetworld.2016.882-887
29. Stich, A.N.; Rosenkrantz, W.S.; Griffin C.E. Clinical efficacy of low-level laser therapy on localized canine atopic dermatitis severity score and localized pruritic visual analog score in pedal pruritus due to canine atopic dermatitis. *Vet Dermatol*. **2014**, 25(5), 464-474.
30. Kazanbaev, R.T.; Prokhorenkov, V.I.; Yakovleva, T.A.; Maksimenko V.G. Use of chitosan compounds photophoresis in the experiment on the model of contact allergic dermatitis. *Siberian Medical Review*. **2014**, 2(86), 27-29.
31. Geynits, A.V. Moskvina S.V. *Laser therapy in cosmetology and dermatology*. Triada: Moscow–Tver, 2010.
32. Wuersch, K.; Brachelente, C.; Doherr M. et al. Immune dysregulation in flea allergy dermatitis – a model for the immunopathogenesis of allergic dermatitis. *Vet Immunol Immunopathol*. **2006**, 110(3-4), 311-323.
33. Zhao, L.; Jin, H.; She R. et al. A rodent model for allergic dermatitis induced by flea antigens. *Vet Immunol Immunopathol*. **2006**, 114(3-4), 285-296.
34. Kozhekin, V.V.; Remedko, O.A.; Tkachev A.M.; Ekuk S.A. Intravenous laser blood illumination and oxygen transport function. *Anaesth. and Intensive Care*. **1995**, 1, 42–43.
35. Kozhura, V.L.; Kirsanova, A.K.; Novoderzhkina, I.S.; Beresina T.L. Low energy laser illumination of blood as a method of preventing the decompensation of blood circulation with hemorrhagic shock. *Anaesth. and Intensive Care*. 1999, 1, 47–51.
36. Vasilyeva, L.V. Clinical and genetic prognosis of the effectiveness of different types of laser therapy in patients with bronchial asthma. Abstract of the thesis. Doctor of medical sciences. Voronezh, 1999.
37. Khakimov, I.S. Intravenous laser blood irradiation and reimplantation of thyroid tissue in the surgical treatment of diffuse goiter. Abstract of the thesis. Candidate of medical sciences. Moscow, 1994.
38. Konovalov, E.P. Intravascular laser blood irradiation (ILBI) in the comprehensive treatment of purulent-septic complications of acute surgical diseases of the abdominal cavity organs. Abstract of the thesis. Candidate of medical sciences. Kiev, 1988.



© 2017 by the authors. Licensee Preprints, Basel, Switzerland. This article is an open access article distributed under the terms and conditions of the Creative Commons by Attribution (CC-BY) license (<http://creativecommons.org/licenses/by/4.0/>).